

See discussions, stats, and author profiles for this publication at: <https://www.researchgate.net/publication/357678350>

Sinus laser-assisted closure (SiLaC®) for pilonidal disease: results of a multicentre cohort study

Article in *Techniques in Coloproctology* · January 2022

DOI: 10.1007/s10151-021-02550-4

CITATION

1

READS

256

4 authors, including:



Tania Sluckin

Academisch Medisch Centrum Universiteit van Amsterdam

16 PUBLICATIONS 58 CITATIONS

[SEE PROFILE](#)



Sanne Hazen

Amsterdam University Medical Center

13 PUBLICATIONS 16 CITATIONS

[SEE PROFILE](#)



Robert Smeenk

Albert Schweitzer Ziekenhuis

10 PUBLICATIONS 56 CITATIONS

[SEE PROFILE](#)


Some of the authors of this publication are also working on these related projects:



Drug dosing in patients after bariatric surgery [View project](#)



Sinus laser-assisted closure (SiLaC®) for pilonidal disease: results of a multicentre cohort study

Tania C. Sluckin¹ · Sanne-Marije J. A. Hazen² · Robert M. Smeenk² · Ruben Schouten¹ 

Received: 10 July 2021 / Accepted: 25 November 2021
© Springer Nature Switzerland AG 2021

Abstract

Background An emerging and promising minimally invasive treatment for pilonidal disease (PD) is sinus laser-assisted closure (SiLaC®). Previous studies have shown encouraging results concerning safety, patient satisfaction, wound healing and acceptable recurrence rates. This study investigated outcomes for a large cohort of PD patients treated with SiLaC®.

Methods A multicentre cohort study with a prospective design and partial retrospective data collection for patients with PD treated with SiLaC® in three hospitals in the Netherlands (Albert Schweitzer Hospital, Flevoziekenhuis and Medical Centre Zuiderzee) from January 1st 2017 to March 1st 2020. The primary outcome was recurrence. Secondary outcomes were incidence of complete wound closure, time until wound closure, postoperative complications, ability to perform daily activities and reported patient satisfaction.

Results A total of 311 patients were included with a median follow-up of 10 months (range 1–52 months). The recurrence rate after one SiLaC® treatment was 26% with 7% experiencing incomplete wound closure, resulting in an initial success rate of 66% after one SiLaC® procedure. This increased to 92% and 98% after two and three SiLaC® procedures, respectively. Mean time until wound closure was 6 weeks (range 1–24 weeks). Seven patients (2%) were still unsuccessfully treated after three SiLaC® treatments and required additional and extensive surgery. Mean time to perform regular daily activities including working was 6 days (range 0–42 days) and the vast majority of patients (84%) did not require painkillers or only paracetamol. Twelve patients (4%) developed a postoperative wound infection. The mean satisfaction score was 9 (range 5–10).

Conclusions SiLaC® is a promising minimally invasive treatment for PD with high patient satisfaction and an acceptable success rate. These results suggest that SiLaC® could be used as a safe and effective primary treatment for PD.

Keywords Pilonidal disease · Minimally invasive treatment · SiLaC®

Introduction

Pilonidal disease (PD) is a chronic inflammation mostly located in the natal cleft, caused by the presence of subcutaneous hairs of different possible origins, which lead to sinus formation and painful cysts. PD appears to occur mainly in males aged 16–26 years and while the aetiology is still not

clearly defined, excessive body hair, obesity and a sedentary lifestyle have all been identified as risk factors [1, 2]. PD has a high disease burden and a negative impact on the quality of life [3].

There are numerous surgical treatments currently used for PD of which surgical excision of the sinuses and tracts with either a primary or secondary closure technique is most commonly chosen [2, 4–6]. Both of these techniques are associated with risks of impaired or delayed wound healing, infection, persistent pain with a chance of recurrence up to 20% [2, 7, 8]. Off-midline closure techniques, such as the Bascom cleft lift, Karydakis or Limberg flap are a better alternative with fair wound healing times and low recurrence rates for patients with persistent, recurrent or complex PD [2, 5, 6, 9–11]. However, a successful minimally invasive technique with an equally low recurrence rate and wound

Tania C. Sluckin and Sanne-Marije J. A. Hazen are joint first authors.

✉ Ruben Schouten
ruschouten@flevoziekenhuis.nl

¹ Department of Surgery, Flevoziekenhuis, 1 Hospitaalweg, 1315 RA Almere, The Netherlands

² Department of Surgery, Albert Schweitzer Hospital, Dordrecht, The Netherlands

healing time would be ideal for this predominantly young patient group, especially for those with limited PD.

One minimally invasive technique with potential is pit picking with a sinus laser-assisted closure (SiLaC®). Various studies have found laser treatment for PD to be effective, with high success rates ranging from 85 to 92% [2, 3, 10–13]. The radial laser probe closes the sinus tracts through one or more small openings. However, studies investigating the SiLaC® have predominantly been performed in single centre cohorts with short-term outcomes [10, 11].

The present study provides results of the first multicentre cohort study with the largest patient group with mixed staging (primary and recurrent disease). This study aimed to evaluate the safety, efficacy and satisfaction outcomes of the SiLaC® treatment from January 1st 2017 to March 1st 2020 in three Dutch hospitals.

Materials and methods

Patient selection

The laser procedure (SiLaC®) was introduced in the Netherlands in 2015. Included patients were treated with SiLaC® between January 1st 2017 and March 1st 2020 in three Dutch hospitals (Albert Schweitzer Hospital, Flevoziekenhuis and Medical Centre Zuiderzee). Inclusion criteria were: (a) primary or recurrent PD, (b) laser procedure performed and (c) 16 years or older. Data for this study was collected prospectively, but missing data and the last follow-up outcomes were collected retrospectively. Short-term follow-up was conducted during outpatient clinic visits. Long-term evaluation during the retrospective data collection was conducted via telephone interviewing.

Primary and secondary outcomes

The primary outcome was recurrence of PD, defined as a return of symptoms of PD after a period of remission (healed skin without symptoms). Secondary outcomes were the incidence of incomplete wound closure (i.e., persistent disease), postoperative complications, postoperative pain (using the visual analogue scale [VAS] score), time until the closure of the wound(s), ability to perform daily activities and reported patient satisfaction score. Incomplete wound closure was defined as a persistent open sinus without closure of the skin, with or without symptoms.

Technique

All three hospitals used the same technique, demonstrated in Fig. 1a–f and described in detail elsewhere [14]. SiLaC® is performed using local, locoregional or general anaesthesia,

depending on the extent of disease and on the preference of the patient and surgeon. Patients are treated in the operating room (OR) with local, locoregional or general anaesthesia, or in the outpatient department (OPD) with local anaesthesia. SiLaC® is performed for persistent pilonidal pits, cavities or tracts. Active abscesses are not treated with SiLaC® but with acute drainage and SiLaC® after a minimum of 6 weeks.

Patients are placed in a lateral position. After shaving and disinfection of the skin with alcoholic chlorhexidine, double strong tape is placed on the buttock to increase exposure. Local anaesthesia is administered with 20 ml bupivacaine or ropivacaine, functioning as an anesthetic and as a medium to increase tumescence by increasing pressure along the sinus walls. The sinoidal pits are enlarged with a biopsy core punch (3–8 mm depending on the pit size). Hair and debris are removed from the sinus tracts with a surgical spoon. Saline water is used for debris washout.

A radial diode laser probe at 1470 nm wavelength is used for delivering homogeneous (360 degrees) energy to the surrounding epithelium to destruct the epithelium and create oedema for collapsing of the tract. A “preparatory laser treatment” is first performed to clean the tracts additionally to the debridement with a sharp spoon, as it might extract extra hair(s) or debris. After this “preparatory treatment” the sinus tracts are again cleansed with a surgical spoon and water. During the definitive procedure, the probe is withdrawn at an approximate speed of 1 cm per 2–3 s, causing the small sinus tracts to shrink and close. Afterwards, sterile dressings are applied.

Postoperative instructions

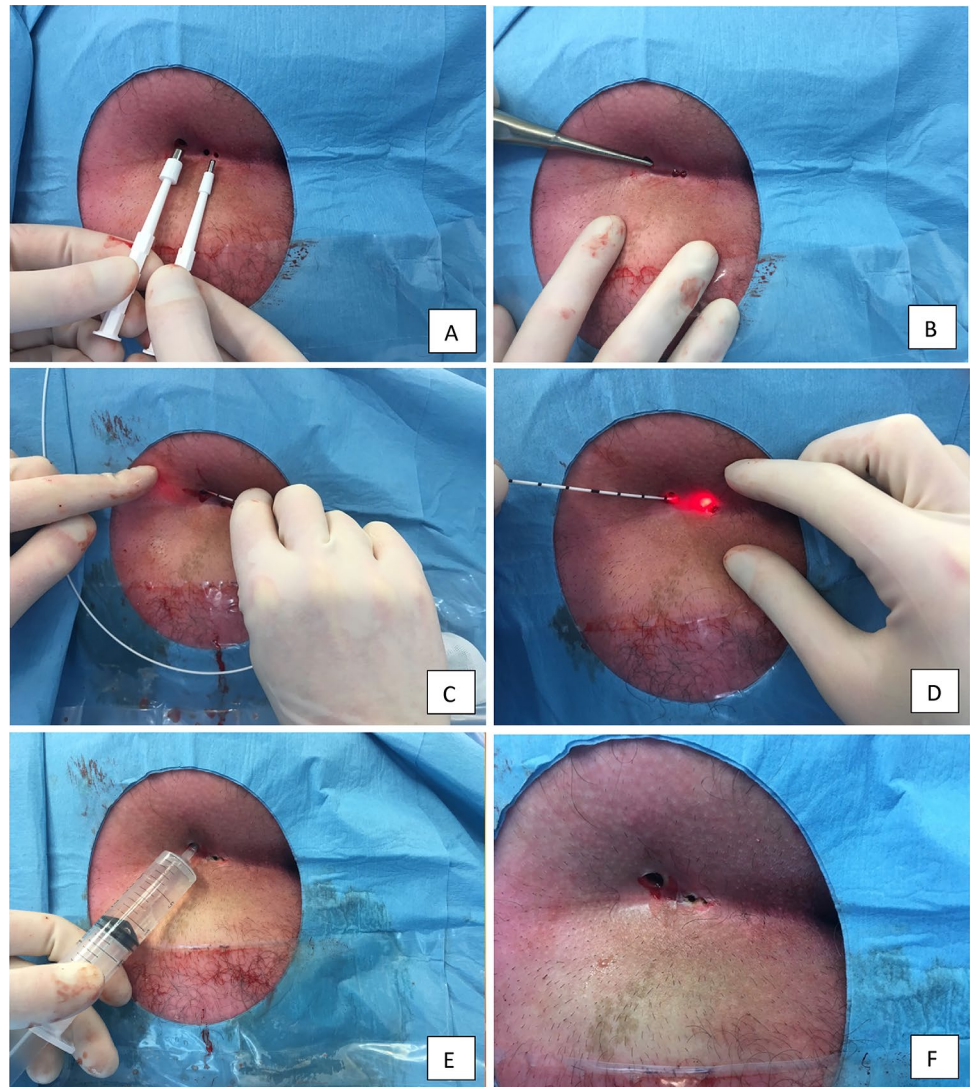
During the first postoperative period (2 weeks), patients were instructed to keep the biopsy wounds open with a thin cotton swab to prevent premature closing of the skin, as wound fluid should be drained. Patients were instructed to use analgesia when necessary. Patients were seen in the outpatient department after 1,3 and 6 weeks, and if necessary 3 months, after the procedure to evaluate wound healing and closure and to detect any persistent sinus activity or early recurrences.

Patients were contacted after a minimum of 6 months to investigate symptoms that could indicate the return of disease activity. In the initial prospective follow-up, patients completed questionnaires regarding postoperative pain and wound healing.

Statistical analysis

Perioperative data was obtained from the electronic patient files. Patient data was coded by a random number in a separate file and with a key code anonymously stored in

Fig. 1 SiLaC® procedure with radial diode 1470 nm probe for pilonidal disease. A: pits are enlarged with a biopsy core punch. B: hair and debris are removed from the sinus tract. C: a preparatory treatment of the sinus tract to clean the tract. D: definitive laser treatment where the laser is withdrawn at an approximate speed of 1 cm per 2–3 s, causing the small tracts to shrink and close. E: saline washout. F: final result, whereafter sterile dressings are applied. SiLaC® = sinus laser-assisted closure



Castor EDC. Data was analysed using descriptive statistics in SPSS (version 26.0). Continuous variables are expressed as mean with a standard deviation (SD), while dichotomous variables are expressed as a number, *n*, with percentages. A *p*-value < 0.05 was considered statistically significant.

Written informed consent was obtained from all patients. This study was conducted according to Dutch law and was approved by a medical ethics committee.

Results

Baseline characteristics are presented in Table 1. A total of 371 patients were eligible for inclusion in this multi-centre study: 148 patients from Albert Schweitzer Hospital (ASZ), 69 patients from Flevoziekenhuis (FZ) and 94 from Medical Centre Zuiderzee (MCZ). Sixty patients for

whom no follow-up data was available and who could not be contacted by telephone, had to be excluded, resulting in a total of 311 patients for analysis.

There were no significant differences in sex or age between the patients from these three hospitals. For the total cohort the mean age was 27 years (SD 10.2) and 77% were male. The cohort consisted of 218 patients (70.1%) with primary disease and 93 patients (29.9%) with recurrent disease; 33 of these patients had previously received laser treatment for their PD. SiLaC® was performed significantly more often in the OPD in FZ compared to ASZ and MCZ (46% versus 11% and 0% respectively). This was due to the fact that the procedure was first adopted in MCZ and therefore performed in the operating room (OR). ASZ treated patients with recurrent disease more often than FZ and MCZ (39% versus 29% and 16% respectively).

Table 1 Baseline characteristics

Baseline characteristics	
Patients per hospital, <i>n</i> (%)	
Albert Schweitzer Hospital	148 (47.6)
Flevoziekenhuis	69 (22.2)
Medical Centre Zuiderzee	94 (30.2)
Age, mean (SD)	27.3 (10.2)
Sex, <i>n</i> (%)	
Male	240 (77.2)
Female	71 (22.8)
Follow up in months, mean (SD)	9.9 (7.1)
Operation location, <i>n</i> (%)	
Operating room	263 (84.6)
Outpatient department	48 (15.4)
Disease, <i>n</i> (%)	
Primary disease	218 (70.1)
Recurrent disease	93 (29.9)
Crohn's disease present, <i>n</i> (%)	5 (1.6)
Number of previous operations, <i>n</i> (%)	
0	207 (66.6)
1	67 (21.5)
2	19 (6.1)
3	11 (3.5)
4	7 (2.3)
Previous laser treatment, <i>n</i> (%)	33/304 (10.8)
Duration of symptoms in weeks before initial presentation, mean (SD)	37 (53.3)
Number of pits, mean (SD)	2 (1.5)

Surgical outcomes

Surgical outcomes can be found in Table 2. All treatments in the OPD and the OR were day-care surgery. No patient required hospital admission. The median operation time was 16 min (range 7–48 min, interquartile range (IQR) 6, mean 16.2 min). The difference in operation location did not result in a significant difference in recurrences (27.4% recurrence after a procedure in the OR versus 20.8% in the OPD, $p=0.379$) nor in postoperative pain (50% OR used painkillers versus 48.6% OPD, $p=0.138$). There was a significant difference in overall postoperative complications which all occurred after treatment in the OR (16 patients, 10.2% versus 0 patients, $p=0.025$). Patients treated in the OR received > 1000 Joules more often than those treated in the OPD, but this was not significant (41.9% vs. 35.9% respectively, $p=0.473$).

The mean number of pits was 2 ± 1 (range 1–7 pits) without a significant relation between the number of pits and postoperative complications ($p=0.190$), pain ($p=0.666$) or recurrences ($p=0.602$). For the SiLaC® procedure a mean of 932 Joules was administered (range 53–3340 Joules).

Table 2 Surgical outcomes

Surgical outcomes	
Operation duration in minutes, mean (SD)	16 (6.3)
Joules, mean (SD)	932 (719)
Perioperative complications	
Bleeding	1 (0.3)
Postoperative painkillers, <i>n</i> (%)	
None	173 (55.6)
Paracetamol	88 (28.3)
NSAID's	46 (14.8)
Tramadol	2 (0.6)
Morphine	2 (0.6)
Use of painkillers in days, mean (SD)	2.9 (3.4)
Postoperative complications	
Wound infection	12/203 (5.9)
Abscess	4/203 (1.9)
Duration until wound closure in weeks, mean (SD)	5.9 (3.4)
Time until return to work/sport in days, mean (SD)	6 (5.8)
Patient satisfaction (1–10), mean (SD)	9 (1.1)

NSAIDs nonsteroidal anti-inflammatory drugs

Administering a larger number of Joules (> 1000 Joules versus < 1000 Joules) was not related to more complications (2.5% versus 1.4% respectively, $p=0.837$), postoperative pain (41.3% versus 50.9% respectively, $p=0.141$) or recurrences (27.3% versus 28.2% respectively, $p=0.884$). The mean time until wound closure was almost 6 weeks (5.9 weeks, SD 3.4 weeks with a range from 1 to 24 weeks). Incomplete wound closure was observed in 23 patients after the first laser treatment (7.4%).

One patient had perioperative bleeding (1/311, 0.3%) and 16 patients (5.1%) had postoperative complications (4 abscesses and 12 wound infections). One hundred thirty-eight patients (44%) reported using painkillers postoperatively. Painkillers were used for a mean of 2.9 ± 3.4 days (range 1–15 days) and the mean postoperative visual analogue score (VAS) for pain was 2.5 ± 2.9 (range 0–10). Mean time until performing all daily activities again including working was 6 days ± 5.8 (range 0–42 days). Patients reported a mean satisfaction score of 9 ± 1.1 out of 10 (on a scale from 1 [not satisfied] – 10 [very satisfied]) for the entire treatment trajectory.

Recurrence

Eighty-two patients (26.4%) reported a recurrence and 23 patients (7.4%) had incomplete wound closure/persistent disease. Recurrence occurred on average 19 ± 15.1 weeks after the first procedure and significantly more often in patients who presented with primary disease than those with recurrent disease (50/82 (61.0%) versus 32/82 patients (39.0%)).

respectively ($p=0.049$). No other variables, such as operation time, age or sex, were significantly associated with the development of a recurrence.

The percentage of patients that did not develop a recurrence of PD after one laser procedure was 73.6%. An additional 7.4% had incomplete wound closure/persistent disease. This means that the overall success percentage after one laser procedure was 66.2%. These patients did not have a persistent open sinus and did not experience a recurrence during the follow-up period (mean 10 months, range 1–52 months). Eleven patients who had a recurrence after their first laser treatment underwent a debridement or incision & drainage treatment due to a recurrence. This was also true for 5 patients after their second operation for PD.

The overall success percentage (closed skin without symptoms) increased to 92.2% for patients who received a second laser procedure after primary failure. Few patients required a third laser procedure, but it was performed as needed and this resulted in a total closure percentage of 97.7%. Seven patients (2.3%) were still unsuccessfully treated after three laser procedures and these patients were treated by a Bascom cleft lift procedure.

Discussion

This multicentre study of 311 patients is, to the best of our knowledge, the largest cohort to date reporting outcomes of patients treated with SiLaC® for PD. The primary success rate (closed wound and no recurrence) in this series is 66%. After consecutive laser treatment this rate can rise significantly with no higher chance of postoperative complications, which our results indicate are already very low after this procedure. Therefore, this study confirms the results of previous reports that SiLaC® is a safe and effective minimally invasive treatment with a high patient satisfaction. As 30% of the cohort already had recurrent disease and the results are the same in primary and recurrent disease, this suggests that SiLaC® could be effective for all stages of PD.

This study found a recurrence rate of 26% and persistent disease rate of 7%, which is higher than reported in previous, smaller populations (5–15%) [2, 3, 11]. The follow-up period of this cohort is somewhat longer compared to other studies and these additional months may have allowed for the incidence of a recurrence to be noted, compared to other studies with shorter follow-up time. Longer follow-up time should be strived in future studies as the rates found here may indicate a significant role for 'late' recurrences.

Surgical excision is still the primary method of treating PD [6]. Excision of PD with secondary wound healing remains common practice in the Netherlands, despite the long and difficult wound healing process. As known from international reports and guidelines, this treatment option

results in long wound healing times and wound care burden for young patients that sometimes are unable to work or study for 3–6 months [5]. Minimally invasive procedures gain popularity to provide an acceptable health burden for patients that actively participate in society. Besides pit picking with phenol treatment, endoscopic treatment or Bascom I procedures [2, 5, 6, 10, 11], additional laser treatment is a relatively novel treatment option. The major advantages of minimally invasive techniques are that patients tolerate it well due to minimal pain, there is the option to perform the procedure under local anaesthesia in the OPD day-care surgery and the ability to quickly return to daily activities within a few days. Our results confirm these advantages.

Our results are not comparable with those from a recent systematic review regarding the laser treatment of PD [15]. Romic et al. examined 10 studies between 2017 and 2020 and found that with a median follow-up of 12 months, 95% of patients achieved primary healing, which improved to 96.6% after repeated treatment. Our initial success rate was much lower, but perhaps more realistic. Usually new techniques are described with amazing results, but when it is repeated by other groups they often do not reach the same results. The healing rate after a second procedure is more in line with our results for patients requiring a second or third laser treatment. Romic et al. also demonstrated other advantages of this treatment, such as the predominant use of local anaesthesia, day-care surgery and high rates of patient satisfaction, though also limited by studies with short follow-up times (median 12 months). In addition, two comparative studies comparing laser treatment to excision for chronic PD both found significantly lower pain and higher satisfaction rates with even lower (3.3% vs. 16.7%, but not statistically significant) recurrence rates [1, 16]. Furthermore, the newly updated German and Italian guidelines for PD present laser treatment as a patient-friendly technique with quicker healing times compared to standard excision, at the cost of somewhat higher recurrence rates. Though no official recommendation is made, considering the novelty of the laser treatment, these definite advantages are mentioned and should be considered [17, 18].

However, there are drawbacks to minimally invasive treatment. This treatment does not act on some of the risk factors for PD, such as the deep natal cleft or bad hygiene. Also, wound closure in the midline is known to result in more recurrences [6, 19] and laser treatment ends up small wounds in the midline. Therefore, as already stated in previous reports [20], this probably explains the higher recurrence and persistent disease rates. While aware of this drawback, we still believe that laser treatment deserves a place in the treatment of PD, considering that the results indicate its effectiveness and the high rates of patient satisfaction with minimal side-effects. The focus should now be on the proper selection of patients, to increase the success rate. A

classification system could be used, but unfortunately a validated classification system for PD is not available. One possibility is for minimally invasive treatments to focus on the “simple or small” PD, where an excision may be overtreatment. But, although the present study does not necessarily show this, complex recurrent PD necessitates more aggressive treatment, in which the choice excision with closure outside the midline should be preferred [19–21]. Currently, the Dutch prospective multicentre Snapshot study ‘PITS’ is prospectively including patients with PD to investigate which different surgical treatments are being performed and to analyse their outcomes such as recurrences, wound healing and quality of life. This study should help to create suitable selection criteria for particular treatments for patients with PD.

SiLaC® begins with pit picking, the extraction of hair and debris, followed by the laser treatment. Iesalnieks et al. investigated 157 patients who received only pit picking for PD over a 3-year period and 17% of their population had a recurrence within 7 months [22]. The additional advantage of SiLaC® laser treatment compared to pit picking alone needs to be examined with specific focus on appropriate patient selection. A future randomised controlled trial from our centres will investigate this by randomly assigning patients to ‘laser and pit-picking’ or ‘pit-picking’ alone. This study can then reveal the potential additional value of the SiLaC®.

The current study has several limitations. Firstly, one of the three centres closed during the follow-up period meaning that 60 eligible patients had to be excluded. It is possible that the outcomes of these 60 patients might have had a significant impact on the true success rate which should be considered. Secondly, the majority of this cohort was analysed retrospectively, therefore some important variables are limited due to missing data. The mean follow-up time in our study was only 10 months (with a range of 1–52 months) which is not ideal as recurrences may occur after this time period. This limited follow-up time should be prolonged in future studies Table 3.

Conclusions

Laser treatment for PD is a safe and patient-friendly procedure with acceptable success rates after one to three laser procedures. Patients reported a high satisfaction, could return to work quickly and the majority did not require painkillers. However, a longer follow-up is necessary to estimate the true recurrence rates with larger samples.

Minimally invasive treatment options should be a part of the surgical treatment options available for PD as an alternative to surgical excision. Future research should consider a

Table 3 Recurrences after SiLaC®

Outcomes of recurrent disease	
Recurrence, <i>n</i> (%)	82/311 (26.4)
Incomplete wound closure after 1st SiLaC®, <i>n</i> (%)	23/311 (7.4)
Weeks until recurrence, mean (SD)	19.9 (15.1)
Recurrence after second laser treatment, <i>n</i> (%)	24/82 (29.3)
Weeks until second recurrence, mean (SD)	5.5 (3.9)
Recurrence after third laser treatment, <i>n</i> (%)	7/22 (31.8) 2 missing
Treated successfully with one SiLaC® procedure	229/311 (73.6)
Treated successfully with two SiLaC® procedures	287/311 (92.2)
Treated successfully with three SiLaC® procedures	304/311 (97.7)

SiLaC® sinus laser-assisted closure

randomized clinical trial to investigate the additional value of laser over pit picking and debridement alone.

Funding No funding was received for this study.

Declarations

Conflicts of interest All authors declare to have no conflicts of interests.

References

1. Yardimci VH (2020) Outcomes of two treatments for uncomplicated pilonidal sinus disease: karydakis flap procedure and sinus tract ablation procedure using a 1470 nm diode laser combined with pit excision. *Lasers Surg Med* 52(9):848–854
2. Pappas AF, Christodoulou DK (2018) A new minimally invasive treatment of pilonidal sinus disease with the use of a diode laser: a prospective large series of patients. *Colorect Dis* 20(8):O207–O214
3. Georgiou GK (2018) Outpatient laser treatment of primary pilonidal disease: the PiLaT technique. *Tech Coloproctol* 22(10):773–778
4. Milone M, Velotti N, Manigrasso M, Anoldo P, Milone F, De Palma GD (2018) Long-term follow-up for pilonidal sinus surgery: A review of literature with metaanalysis. *Surgeon* 16(5):315–320
5. Bi S, Sun K, Chen S, Gu J (2020) Surgical procedures in the pilonidal sinus disease: a systematic review and network meta-analysis. *Sci Rep* 10(1):13720
6. Stauffer VK, Luedi MM, Kauf P, Schmid M, Diekmann M, Wieferrich K et al (2018) Common surgical procedures in pilonidal sinus disease: A meta-analysis, merged data analysis, and comprehensive study on recurrence. *Sci Rep* 8(1):3058
7. Arnous M, Elgandy H, Thabet W, Emile SH, Elbaz SA, Khafagy W (2019) Excision with primary midline closure compared with Limberg flap in the treatment of sacrococcygeal pilonidal disease: a randomised clinical trial. *Ann R Coll Surg Engl* 101(1):21–29
8. Käser SA, Zengaffinen R, Uhlmann M, Glaser C, Maurer CA (2015) Primary wound closure with a Limberg flap vs. secondary

- wound healing after excision of a pilonidal sinus: a multicentre randomised controlled study. *Int J Colorect Dis* 30(1):97–103
9. Harju J, Soderlund F, Yrjonen A, Santos A, Hermunen K. Pilonidal Disease Treatment By Radial Laser Surgery (FilaC): The First Finnish Experience. *Scand J Surg*. 2020:1457496920975610.
 10. Dessily M, Charara F, Ralea S, Alle JL (2017) Pilonidal sinus destruction with a radial laser probe: technique and first Belgian experience. *Acta Chir Belg* 117(3):164–168
 11. Dessily M, Dziubeck M, Chahidi E, Simonelli V (2019) The SiLaC procedure for pilonidal sinus disease: long-term outcomes of a single institution prospective study. *Tech Coloproctol* 23(12):1133–1140
 12. Harju J, Söderlund F, Yrjönen A, Santos A, Hermunen K. Pilonidal disease treatment by radial laser surgery (FilaC™): The first finnish experience. *Scand J Surg SJS* 2020:1457496920975610.
 13. Dragoni F, Moretti S, Cannarozzo G, Campolmi P (2018) Treatment of recurrent pilonidal cysts with nd-YAG laser: report of our experience. *J Dermatolog Treat* 29(1):65–67
 14. Alferink M, Atmowihardjo L, Smeenk R, Cadanova D, Schouten R (2019) Pilonidal disease laser therapy: short term results of an observational cohort study. *World J Surg Surgical Res* 2:1143
 15. Romic I, Augustin G, Bogdanic B, Bruketa T, Moric T. Laser treatment of pilonidal disease: a systematic review. *Lasers Med Sci* 2021.
 16. Khubezov DA, Lukanin RV, Krotkov AR, Ogoreltsev AY, Serbryansky PV, Yudina EA (2020) Laser ablation for pilonidal disease. *Koloproktologia* 19(2):91–103
 17. Iesalnieks I, Ommer A, Herold A, Doll D (2020) German National Guideline on the management of pilonidal disease: update. *Langenbecks Arch Surg* 2021:1–12
 18. Segre D, Pozzo M, Perinotti R, Roche B (2015) The treatment of pilonidal disease: guidelines of the Italian Society of Colorectal Surgery (SICCR). *Tech Coloproctol* 19(10):607–613
 19. Iesalnieks I, Deimel S, Schlitt HJ (2013) Karydakias flap for recurrent pilonidal disease. *World J Surg* 37(5):1115–1120
 20. Iesalnieks I, Ommer A, Petersen S, Doll D, Herold A (2016) German national guideline on the management of pilonidal disease. *Langenbecks Arch Surg* 401(5):599–609
 21. Iesalnieks I, Ommer A (2019) The management of pilonidal sinus. *Deutsches Arzteblatt international* 116(1–2):12–21
 22. Iesalnieks I, Deimel S, Schlitt HJ. ["Pit picking" surgery for patients with pilonidal disease: mid-term results and risk factors]. *Der Chirurg; Zeitschrift für alle Gebiete der operativen Medizen*. 2015;86(5):482–5.

Publisher's Note Springer Nature remains neutral with regard to jurisdictional claims in published maps and institutional affiliations.